

# A Rare Case of A Complex Odontome Fused to An Upper Wisdom Tooth

Clarence Pace<sup>1</sup>, Richard Crosher<sup>2</sup>, Audrey Pace<sup>3</sup>, Purush Manivasagam<sup>4</sup>

## ABSTRACT

A 22 year old man presented with pain arising from his carious lower left second molar. An Orthopantomogram (OPT) revealed an incidental finding of an odontome fused to an upper wisdom tooth, a finding that to the author's knowledge has never been previously reported. This case also illustrates the value of panoramic radiographs in identifying incidental pathology.

**Keywords:** Fused odontome, Upper wisdom tooth, Incidental findings On radiographs

<sup>1</sup>MD, BChD, MFDSRCS (Eng), MRCS (Glas)  
Specialty Registrar  
Oral and Maxillofacial Surgery,  
Rotherham Hospitals NHS Trust,  
Rotherham, UK  
Phone Number: 00447853237718  
Fax Number: 00441709307639

<sup>2</sup>MBCbB, BDS, FDSRCS, FRCS (Maxfax)  
Consultant Oral and Maxillofacial Surgeon  
Rotherham Hospitals NHS Trust  
Rotherham  
E-mail: Richard.crosher@rothgen.nhs.uk

<sup>3</sup>BChD, MJDFRCS (Eng)  
Teaching Dental Officer  
Rotherham Community Dental Clinics  
Rotherham  
E-mail: paceaudrey@hotmail.co.uk

<sup>4</sup>BDS, MFDSRCS(Eng)  
SHO  
Oral and Maxillofacial Surgery  
Rotherham Hospitals NHS Trust  
Rotherham

## CASE REPORT

A 22 year old male patient presented with pain arising from his grossly carious lower left second molar. An OPT (Figure 1) confirmed deep caries in his tooth but also a displaced upper right wisdom tooth which appeared to be fused to a radio-opaque mass surrounded by a narrow radiolucent zone. Clinical examination of this region was unremarkable. The provisional diagnosis was an odontome but odontogenic tumours entered the differential diagnosis. A CT scan (Figure 2) supported the initial diagnosis. The patient underwent surgical extraction of the second molar and removal of the upper right wisdom tooth and the associated

lesion. A crevicular incision around the 15, 16, 17 and 18 and a relieving incision extending into the buccal sulcus was used for access. Bone was removed and the tooth and odontome excised. The complex odontome was found to be fused to the tooth, the latter being of normal morphology (Figure 3).

## DISCUSSION

Although odontomes are by definition hamartomas of odontogenic origin, they are usually considered developmental anomalies. Tooth development is divided into 3 main stages namely the bud (or initiation stage), cap and bell stage. Complex odontome formation is thought to arise mainly from abnormalities

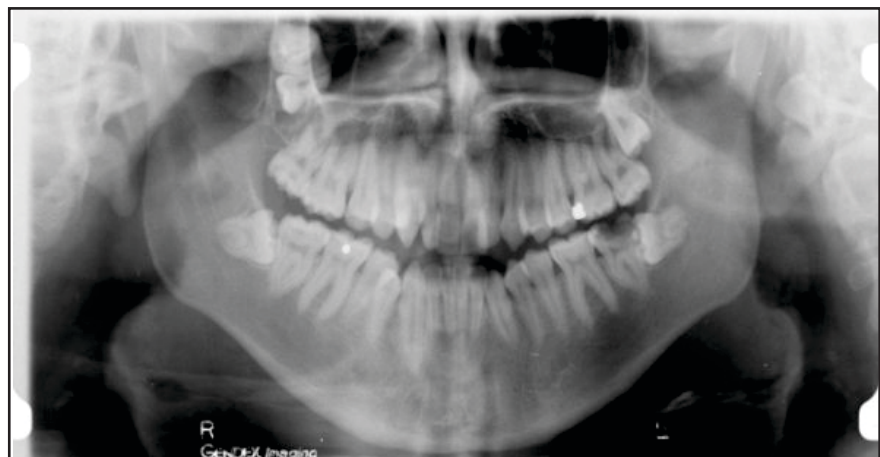
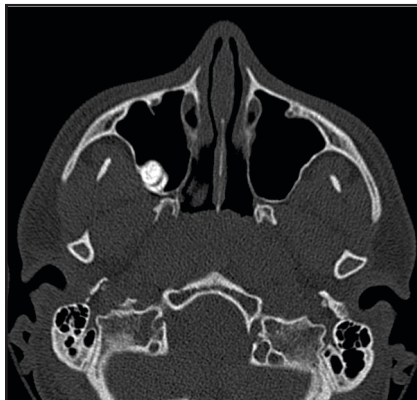

Figure 1: OPT Showing The Unerupted Upper Right Wisdom Tooth Closely

## Contact Author

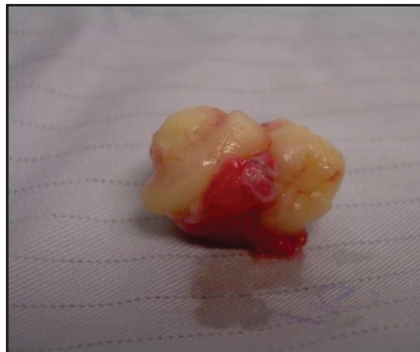Mr. Clarence Pace  
Email: clar.aud@hotmail.com

J Oral Health Comm Dent 2011;5(1)47-48



**Figure 2: Axial Ct Scan Showing The Wisdom Tooth And Associated Mass**

occurring in the bud stage of development where excessive numbers of initiation leads to the formation of uncoordinated cells crowded into one area. On the one hand, a lack of initiation leads to absence of teeth whilst on the other hand excessive growth of the dental lamina which in turn results in additional tooth germs budding off leads to the formation of additional teeth. The exact cause of odontomes is not known but trauma and infection have been suggested as possible aetiological factors (1). These hamartomatous malformations which consist of enamel and dentine with a variable amount of cementum and pulp tissue are classified as compound and complex according to the WHO classification with a variant hybrid sometimes being included when there are elements of both present (2). The main difference between the two types is that the compound odontome consists of toothlets which can easily be diagnosed from radiographs, whilst the complex odontome requires histological confirmation because the calcified structure bears no clinical resemblance to dental structures appearing as a mass of calcified tissue (3).



**Figure 3: Photograph Of Clinical Specimen Clearly Showing The Odontome Fused To The Wisdom Tooth**

Odontomes are much more commonly associated with permanent teeth (4). The majority of compound odontomes occur in the anterior segment of the jaws, whilst the complex type occurs more commonly in the posterior segment. There is no gender or age predilection and they occur more often on the right side than on the left (5). Most cases are diagnosed as incidental findings on radiographs. However odontomes can interfere with the normal eruption process causing an impaction of teeth typically in the anterior maxilla. They can also present with an infection and rarely as an expansion of the jaws particularly if a cyst develops round the odontomes (5). Although odontomes tend to be closely associated to the adjacent teeth and are commonly separated by a septum of bone, to the authors knowledge there have been no previous reports of odontomes fused to a tooth of normal morphology (Figure 3). Fusion is the union between the dentine and / or enamel of two or more separate developing teeth. In the permanent dentition fused teeth are more common in the incisor region. There is some evidence that fusion of teeth is

inherited as a dominant trait (6). It seems likely that whatever process leads to the fusion of otherwise normal teeth could cause the fusion of an odontome to an otherwise normal tooth. Although Complex odontomes fused to lower third molar crowns have been previously described, none have been reported in the upper third molar region. This report not only highlights this rare finding but also illustrates the value of panoramic radiographs in identifying incidental pathology (7, 8).

## REFERENCES

1. Neville, Damm, Allen, Bouquot; Oral and Maxillofacial Pathology; 2<sup>nd</sup> ed. Saunders 2004:p631-632.
2. Kramer IRH, Pindborg JJ, Shear M. Histological typing of Odontogenic tumour. WHO International Histological Classification of Tumours; 2<sup>nd</sup> ed. Berlin Springer 1992. p. 16-21.
3. White, Pharoah. Oral Radiology-Principles and Interpretation 4<sup>th</sup> ed. Mosby 2000. p. 395-397.
4. Hisatomi M, Asaumi JI, Konouchi H, *et al*. A case of complex odontome associated with an impacted lower deciduous second molar and analysis of 107 odontomas. *Oral Dis* 2002;**8**:100-105.
5. Shafer, Hine, Levy. A text book of Oral Pathology; 4th ed. WB Saunders and CO 1993:p308-312.
6. Areal-Lopez I, Silvestre DF, Gil LJJ. Compound odontome erupting in the mouth; fourth year follow up of a clinical case. *J Oral Path* 1992;**21**:285-288.
7. Tetradis S, Kantor ML. Prevalence of skeletal and dental anomalies and normal variants seen in cephalometric and other radiographs of orthodontic patients. *Am J Orthod Dentofacial Orthop* 1999;**116**: 572-577.
8. Asaumi JI, Hisatomi M, Yanagi Y, *et al*. Evaluation of panoramic radiographs taken at the initial visit at a department of paediatric dentistry. *Dentomaxillofac* 2008;**37**:340-343.