

Geminated Maxillary Lateral Incisor with Talon's Cusp – A Rare Case Report

Archna Agnihotri, Nikhil Marwah, Mahesh Goel

ABSTRACT

A rare case of Geminated maxillary lateral incisor with Talon's cusp is reported. In order to relieve the crowding, align the anteriors and to facilitate the eruption of canine it was planned to extract the geminated tooth. The canine after complete eruption was recontoured to the shape of lateral incisor followed by the alignment of anterior teeth.

Key Words: Gemination, Talon's cusp.

Contact Author

Dr. Nikhil Marwah

E-mail: dr_nikhilmarwah@rediffmail.com

J Oral Health Comm Dent 2007;1(2):40-42

Geminated teeth are developmental anomalies of the tooth shape that arise from an abortive attempt by the single tooth bud to divide, resulting in a bifid crown. The etiology is unknown but evidence from case history studies suggests that the anomaly exhibits a hereditary tendency, similar to that affecting the dental lamina and resulting in hyperdontia with the mode of inheritance is probably being either autosomal recessive or dominant with very little penetrance.(1) It appears that gemination is caused by complex interactions among a variety of genetic and environmental factors. They are found more frequently in the primary than in permanent dentition, with a prevalence of approximately 1% and 0.1% respectively and more predilection in maxillary primary incisors and canine.(2)

Talon's Cusp of anterior teeth characterized by the presence of an accessory cusp like structure projecting from cingulum area of cemento-enamel junction is a relatively rare developmental anomaly with prevalence ranging from 0.06% to 7.7%.(3,4) This occurs during the morpho-differentiation stage of tooth development as an outward folding of inner enamel epithelial cells and transient focal hyperplasia of peripheral cells of mesenchymal dental papilla.

A geminated permanent maxillary lateral incisor is an uncommon finding and the association of this geminated tooth with talon's cusp is even rarer finding with only three previous case reports.(5,6,7) The purpose of this article is to present a case report of a geminated maxillary lateral incisor with talon's cusp.

Case Report

A 12 year old male child reported with the chief complaint of malaligned teeth. The patient was second of the two siblings

of parents with no history of consanguinity. No other member of the family was affected by similar dental anomalies. The patient appeared healthy and of normal physical development for his age. There was no history of reported orofacial trauma. Intraoral examination revealed Class I molar occlusion with severe crowding in both the upper and lower arches with relative generalized macrodontia of all the teeth. Right maxillary lateral incisor had a large bifid crown with a talon cusp on the palatal aspect. It was displaced palatally and the two parts of the geminated tooth appeared to be the mirror images of each other (Fig. 1). The Intraoral periapical radiograph and maxillary occlusal radiograph (Fig. 2) revealed that the geminated tooth was impeding the eruption of canine. After the arch analysis, in order to relieve the crowding, align

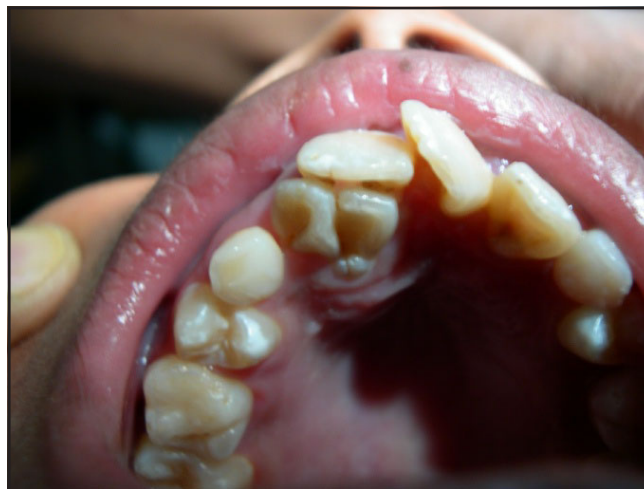

Fig. 1: Clinical presentation of the patient with the geminated teeth and associated talon's cusp

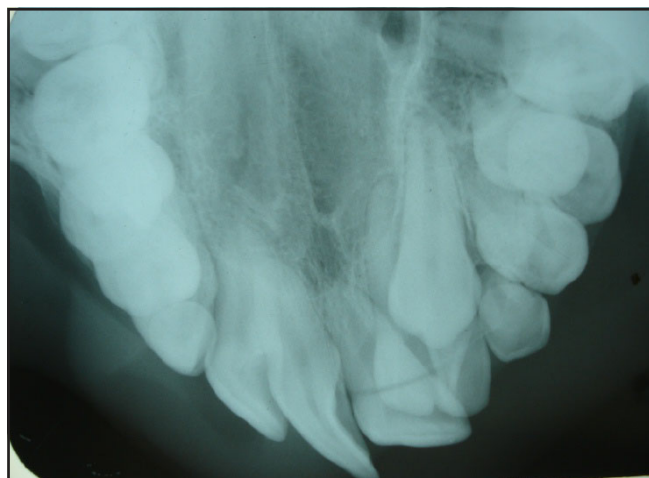


Fig. 2: Maxillary occlusal radiograph

the anteriors and to facilitate the eruption of canine it was planned to extract the geminated tooth. The tooth was extracted under local anesthesia and healing was uneventful and the patient was on follow up. After the eruption of canine it was recontoured to the shape of lateral incisor followed by the alignment of anteriors.

The extracted tooth was again subjected to digital radiography, as it was now possible to examine the tooth in all directions. The radiograph of the extracted tooth revealed that the two halves of the geminated tooth were the mirror images of each other with a single large pulp chamber (Fig. 3).

Ultrasound examination of the extracted tooth showed no significant differences in the reflected echoes at the point of gemination. Bone densitometry examination revealed that the line of gemination was denser as compared to the normal tooth structure but the evidence was not conclusive.

Histological examination revealed that the tooth was geminated at whole of its length with confluent dentine and enamel and a single large pulp chamber. The pulp tissue was not extending into the talon cusp and it was composed only of enamel and dentine (Fig. 4).

The radiographic and histologic findings thus confirmed our clinical diagnosis of gemination of maxillary lateral incisor.

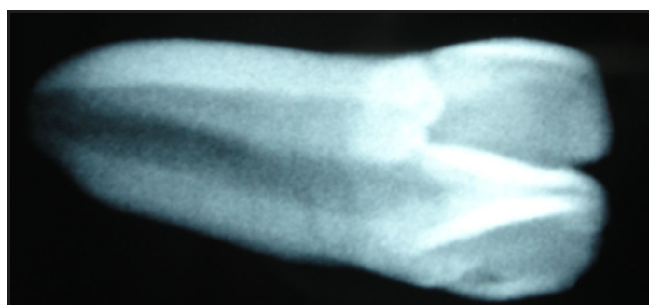


Fig. 3: Digital radiograph of extracted tooth

Discussion

Fusion or gemination are developmental anomalies with inherently bizarre anatomy. These anomalies may develop during tooth bud morpho-differentiation as a result of a developmental aberration of both the ectoderm and mesoderm. Brook and Winter elucidated the difficulty of deciding whether a tooth is fused or geminated and proposed that these anomalies be referred to in a neutral term, such as “double teeth”.⁽⁸⁾ Definite categorization of joined teeth as either germination or fusion however is often difficult.⁽⁹⁾ Several clinical and radiographic criteria are used to distinguish fusion from gemination. Fusion is the incomplete attempt of two tooth buds to fuse into one, whereas gemination is the incomplete attempt of one tooth bud to divide into two. Clinically when the joined teeth are counted as one, a full complement of teeth usually means that the phenomenon represents gemination; less than full complement of teeth usually indicates fusion. A radiographic consideration is the difference in the root configuration often seen between fusion and gemination. In case of fusion there are usually two separate canals, whereas in gemination there is usually one large common root canal.^(8,9) In the present case, the single large pulp chamber with confluent enamel and dentine was present so this can be considered as a case of gemination.

A geminated maxillary incisor requires complex multidisciplinary treatment to preserve its health and restore esthetics.⁽¹⁰⁾ There are different treatment approaches, esthetic quality is usually the determining factor regarding the decision to retain or extract these teeth. One possible treatment involves their extraction with approximation and conversion crowing of the suitable adjacent teeth.⁽¹¹⁾ The second option is surgical division of the double teeth when the degree of fusion is mild.⁽¹²⁾ The third option is selective grinding in order to reduce the width.⁽¹³⁾ A fourth option is to remove these teeth and replace the extracted teeth with an interim removable partial denture until they can be replaced with a fixed bridge or an implant.⁽⁷⁾ In the present case the retention of the

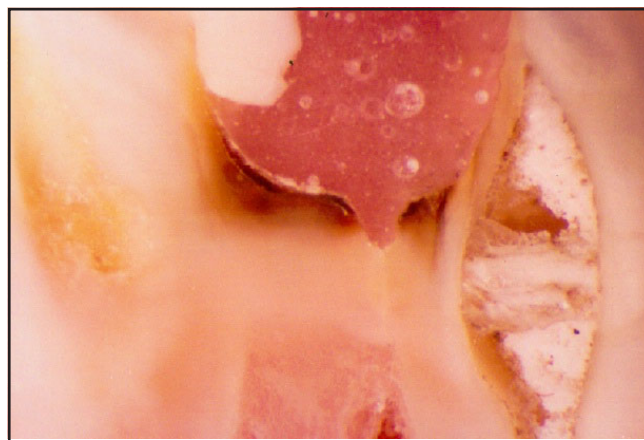


Fig. 4: Histological section of the fused teeth under high power

geminated tooth was not possible as it was causing the impaction of canine and there was no space for aligning the maxillary incisors. In the presence of severe crowding it was impossible to gain space for the alignment of maxillary central incisor as well as for the recontoured and capped geminated tooth along with facilitating the eruption of impacted canine. So it was decided to extract the geminated tooth followed by conversion crowning of canine and alignment.

THE AUTHORS

Dr. Archana Agnihotri

BDS; MDS

Sr. Lecturer

Department of Pedodontics and Preventive Dentistry,
Bhojia Dental College, Baddi,
Himachal Pradesh, India

Reprint requests: Dr. Archana Agnihotri

Dr. Nikhil Marwah

BDS; MDS

Asst. Professor

Department of Pedodontics and Preventive Dentistry,
Govt. Dental College, Rohtak-124001,
Haryana, India

E-mail: dr_nikhilmarwah@rediffmail.com

Dr. Mahesh Goel

BDS; MDS

Asst. Professor

Department of Oral & Maxillofacial Surgery,
Govt. Dental College, Rohtak-124001, Haryana, India

References

1. Stewart RE. The dentition and anomalies of tooth size, form, structure and eruption. *Pediatric Dentistry: scientific foundations and clinical practice*. Stewart RE *et al.* editors St. Louis: C.V. Mosby Co.; 1982.
2. Buenviaje TM, Rapp R. Dental anomalies in children: a clinical and radiographic survey. *ASDC J Dent Child* 1984; 51(1): 42-46.
3. Sedano HO, Carreon Freyre I, Garza de la Garza ML, Gomar Franco CM, Grimaldo Hernandez C, Hernandez Montoya ME *et al.* Clinical oro-dental abnormalities in Mexican children. *Oral Surg, Oral Med, Oral Pathol* 1989; 68(3): 300-11.
4. Chawla HS, Tewari A, Gopalkrishan NS. Talon cusp- a prevalence study. *J Indian Soc Pedod Prev Dent* 1983; 1(1): 28-34.
5. Cullen CL, Pangrazio-Kulbersh V. Bilateral gemination with talon cusp: report of case. *J Am Dent Assoc* 1985; 111(1): 58-9.
6. Al-Omari MA, Hattab FN, Darwazeh AM, Dummer PM. Clinical problems associated with unusual cases of talon cusp. *Int Endod J* 1999; 32(3): 183-90.
7. Hattab FN, Hazza AM. An Unusual case of talon cusp on geminated tooth. *J Can Dent Assoc* 2001; 67: 263-6.
8. Grover PS, Lorton L. Gemination and twinning in the permanent dentition. *Oral Surg, Oral Med, Oral Pathol* 1985; 59: 313-8.
9. Prabhakar AR, Marwah N, Raju OS. Triple Teeth: A Case report of an unusual fusion of 3 teeth. *ASDC J Dent Child* 2004; 71: 32-5.
10. Braun A, Appel T, Frentzen M. Endodontic and surgical treatment of a geminated maxillary incisor. *Int Endod J* 2003; 36(5): 380-6.
11. Mills JRE. Principles and practice of orthodontics. Churchill Livingstone, London 1982; 50-1.
12. Moore KH. A case report of bilateral double teeth. *Br J Orthod* 1984; 11(1): 40-1.
13. Brook AH, Winter GB. Double teeth. A retrospective study of geminated and fused teeth in children. *Br Dent J* 1970; 129(3): 123-30.